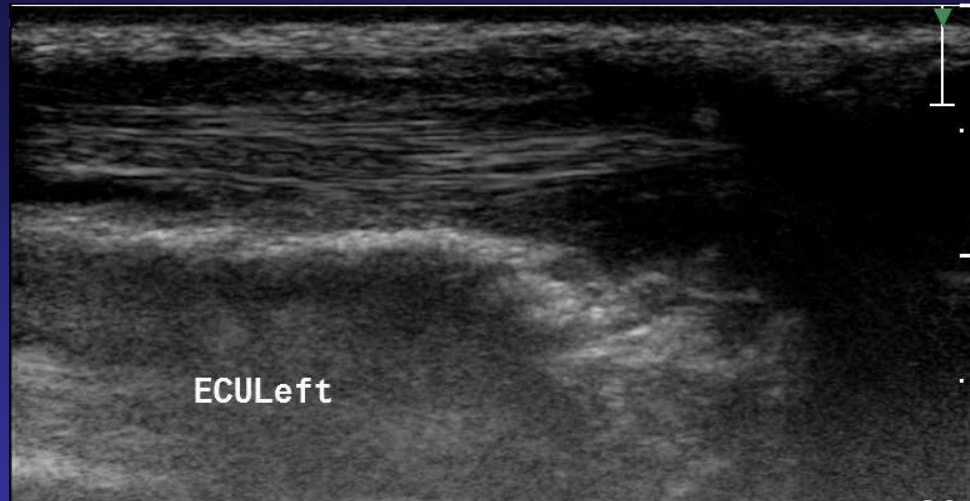
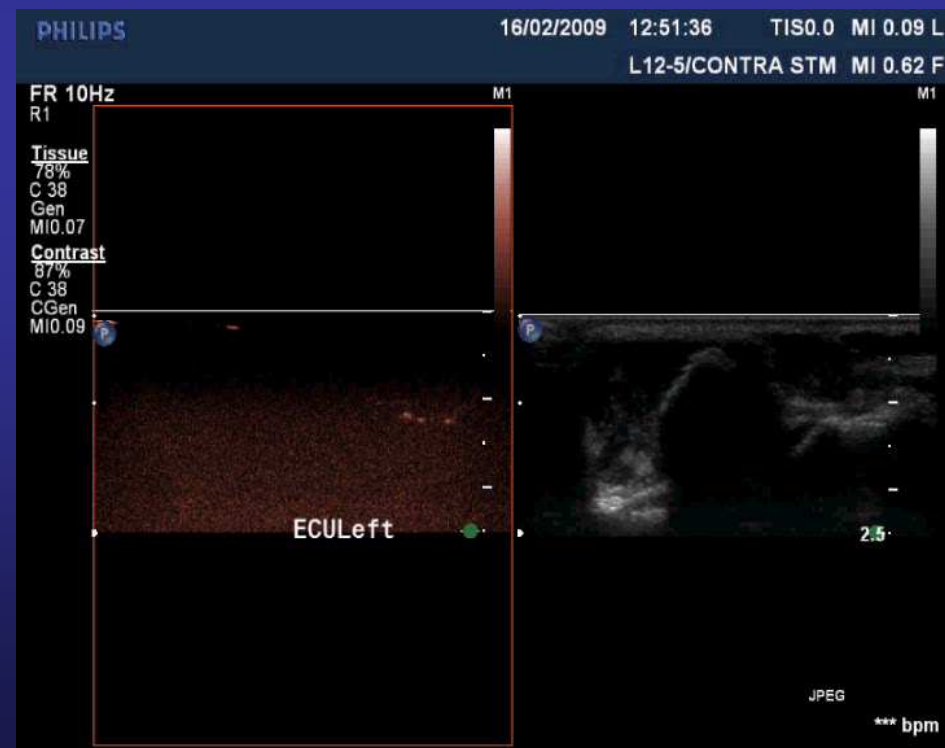

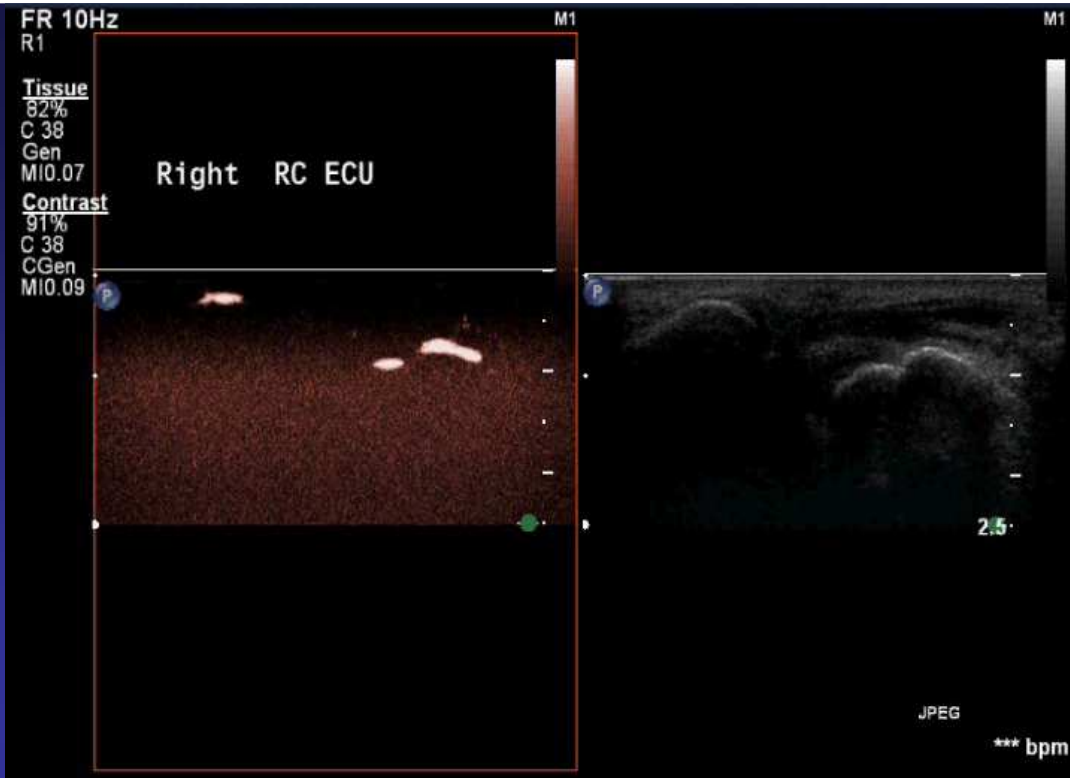CEUS – musculoskeletal cases

Andrea Šprláková-Puková
Department of Radiology
Head of the dept.: Prof. V.Válek
Masaryk University Hospital Brno
Czech Republic

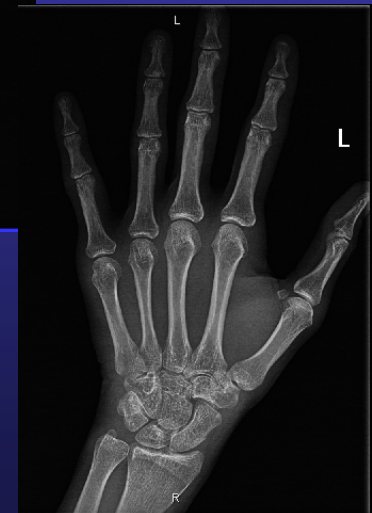
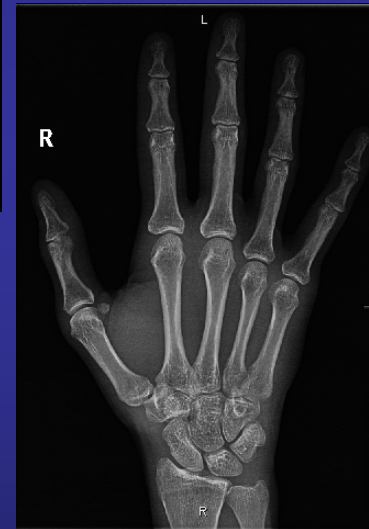
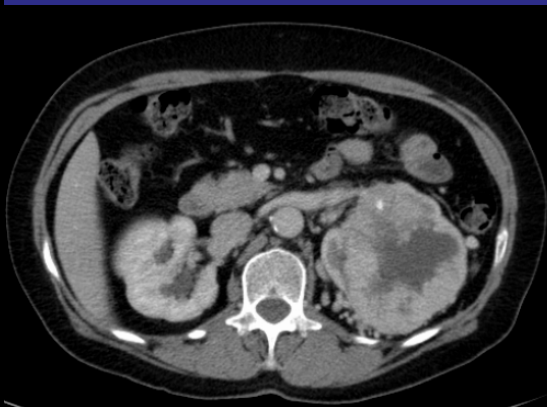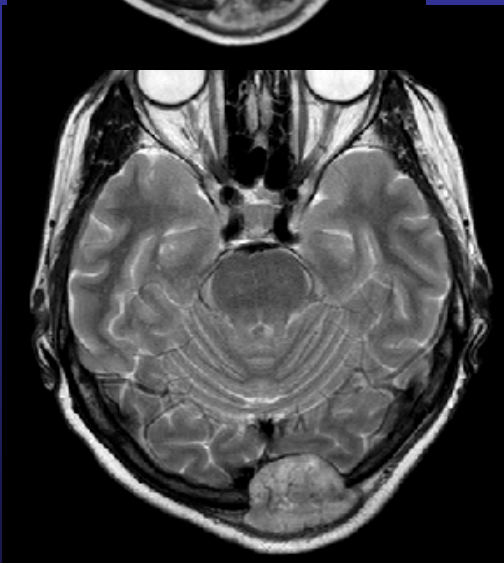

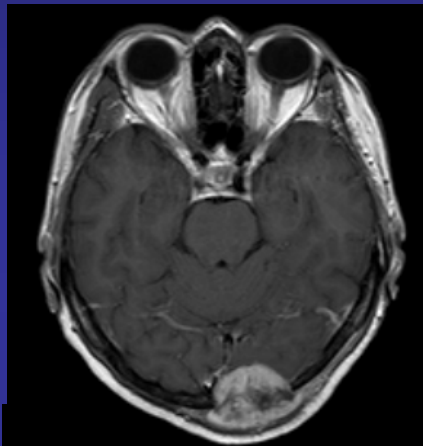
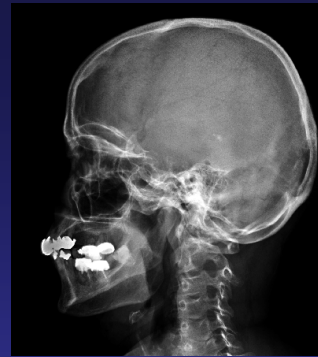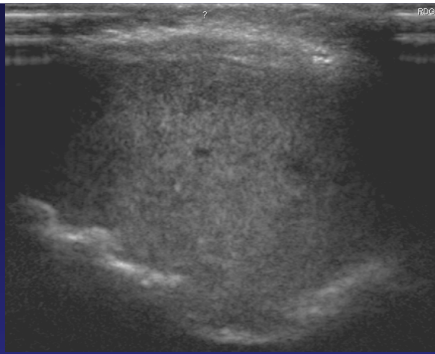
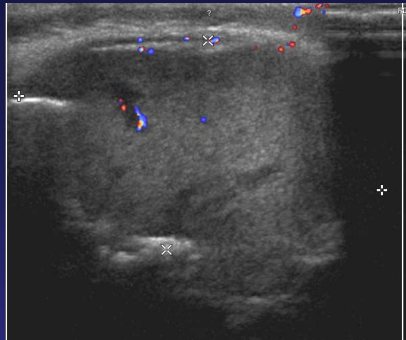
Women 22 years old,
swollen fingers, high ESR,
negative RF and antiCCP





Women, 36 years,
intermittent swollen fingers
since 2008, mother RA,
positive RF and antiCCP





Women 64 years old, trauma (felldown 2 weeks ago), since this time she mentioned resistance in occipital area, susp. hematoma – US – focal lesion with hyperperfusion, X ray – osteolytic lesion , MR CT - RCC

Thank you for your attention.

